

See discussions, stats, and author profiles for this publication at: <https://www.researchgate.net/publication/229538071>

Gingival Zenith Positions and Levels of the Maxillary Anterior Dentition

Article in *Journal of Esthetic and Restorative Dentistry* · April 2009

Impact Factor: 0.81 · DOI: 10.1111/j.1708-8240.2009.00242.x

CITATIONS

38

READS

515

4 authors, including:



Stephen J Chu

New York University College of Dentistry

55 PUBLICATIONS 465 CITATIONS

SEE PROFILE



Christian F J Stappert

University of Maryland, Baltimore

52 PUBLICATIONS 917 CITATIONS

SEE PROFILE



Dennis P Tarnow

Columbia University

158 PUBLICATIONS 5,648 CITATIONS

SEE PROFILE

Gingival Zenith Positions and Levels of the Maxillary Anterior Dentition

STEPHEN J. CHU, DMD, MSD, CDT*
JOCELYN H-P. TAN, DDS[†]
CHRISTIAN F.J. STAPPERT, DDS, MS, PhD, Priv.-Doz.[‡]
DENNIS P. TARNOW, DDS[§]

ABSTRACT

Purpose: The location of the gingival zenith in a medial-lateral position relative to the vertical tooth axis of the maxillary anterior teeth remains to be clearly defined. In addition, the apex of the free gingival margin of the lateral incisor teeth relative to the gingival zeniths of the adjacent proximal teeth remains undetermined. Therefore, this investigation evaluated two clinical parameters: (1) the gingival zenith position (GZP) from the vertical bisected midline (VBM) along the long axis of each individual maxillary anterior tooth; and (2) the gingival zenith level (GZL) of the lateral incisors in an apical-coronal direction relative to the gingival line joining the tangents of the GZP of the adjacent central incisor and canine teeth under healthy conditions.

Materials and Methods: A total of 240 sites in 20 healthy patients (13 females, 7 males) with an average age of 27.7 years were evaluated. The inclusion patient criteria were absence of periodontal disease, gingival recession, or gingival hypertrophy as well as teeth *without* loss of interdental papillae, spacing, crowding, existing restorations, and incisal attrition.

GZP dimensions were measured with calibrated digital calipers for each individual tooth and within each tooth group in a medial-lateral direction from the VBM. GZLs were measured in an apical-coronal direction from a tangent line drawn on the diagnostic casts from the GZPs of the adjacent teeth.

Results: This study demonstrated that all central incisors displayed a distal GZP from the VBM, with a mean average of 1 mm. Lateral incisors showed a deviation of the gingival zenith by a mean of 0.4 mm. In 97.5% of the canine population, the GZP was centralized along the long axis of the canine. The mean distance of the contour of the gingival margin in an apical-coronal direction of the lateral incisors (GZL) relative to gingival line joining the tangent of the adjacent central and canine GZPs was approximately 1 mm.

Conclusion: This investigation revealed a GZP mean value of 1 mm distal from the VBM for the central incisor tooth group. The lateral incisors showed a mean average of 0.4 mm. The

*Clinical associate professor, Department of Periodontology and Implant Dentistry, College of Dentistry, New York University, New York, NY, USA

[†]Prosthodontic resident, New York Hospital Queens, Flushing, NY, USA

[‡]Assistant professor, Department of Periodontology and Implant Dentistry, Department of Biomaterials and Biomimetics, College of Dentistry, New York University, New York, NY, USA; Associate professor, Department of Prosthodontics, Faculty of Dentistry, Albert-Ludwigs-University, Freiburg, Germany

[§]Professor and chairman, Department of Periodontology and Implant Dentistry, College of Dentistry, New York University, New York, NY, USA

canine tooth group demonstrated almost no deviations of the GZP from the VBM. The GZL of the lateral incisors relative to the adjacent central incisor and canine teeth were more coronal by approximately 1 mm. These data could be used as reference points during esthetic anterior oral rehabilitation.

CLINICAL SIGNIFICANCE

The information presented in this article can be clinically applied to reestablish the proper intratooth GZPs of the maxillary anterior teeth during periodontal crown lengthening or root coverage procedures. In addition, the intra-arch gingival level of the lateral incisor gingival zenith relative to the adjacent central and canine teeth can be appropriately established.

(*J Esthet Restor Dent* 21:113–121, 2009)

INTRODUCTION

Gingival esthetics has always been an important component of a beautiful smile. Beautiful restorations surrounded by unattractive gingival tissues can negatively impact on a smile (Figure 1). Gingival health is among the first fundamental esthetic objectives during treatment planning; it is also essential to consider gingival morphology and contour.¹ The ideal

gingival architecture has been described as one that consists of knife-edged gingival margins tightly adapted to the teeth, interdental grooves, and cone-shaped interdental papilla² (Figure 2). Nordland and Tarnow's classification of a normal interdental papilla is one that fills the embrasure space to the apical extent of the interdental contact area.³ Deviation from the normal interdental papilla will

result in an esthetically undesirable gingival “black triangle,” and gingival asymmetry can lead to visual stress and imbalance (Figure 3).^{4,5} Adjunctive therapies, including periodontal plastic surgery, are recommended to optimize gingival contours for restorative treatment in the presence of severe gingival deformity (Figure 4).^{6–8} Understanding the dentogingival interface will allow clinicians to achieve a

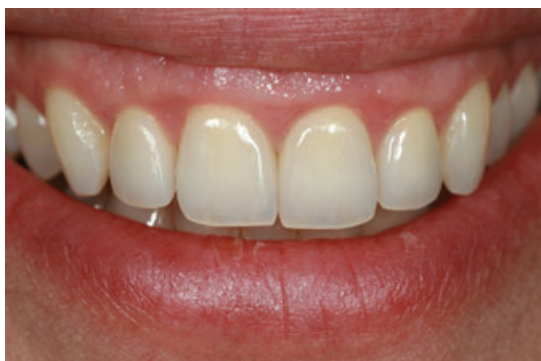

Figure 1. Replacement of full-coverage restorations teeth #7 to 10, with better marginal integrity. Gingival inflammation has improved; however, marginal inflammation still exists because of the nocturnal mouth breathing condition, which detracts from the final appearance of the restorations.

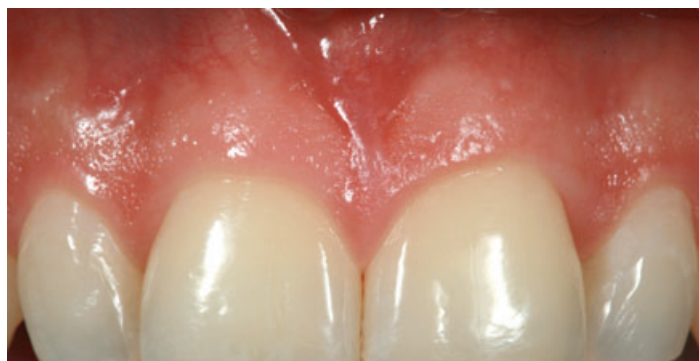

Figure 2. The ideal gingival architecture has been described as one that consists of knife-edged gingival margins tightly adapted to the teeth, interdental grooves, and cone-shaped interdental papilla.

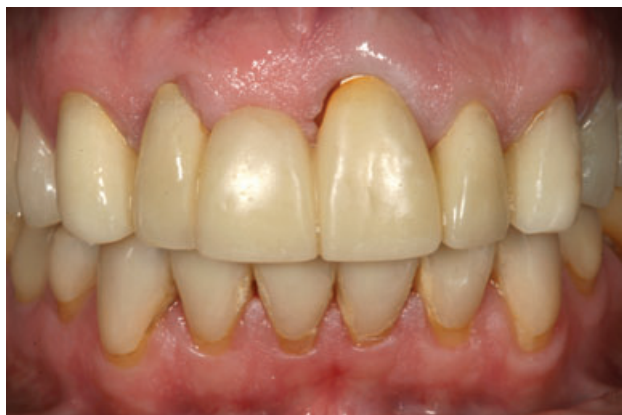

Figure 3. Intraoral view of provisional restorations on teeth #6 to 11 without consideration of the gingival level disharmony, which leads to visual distress and, consequently, deviation from ideal tooth proportion ratios.

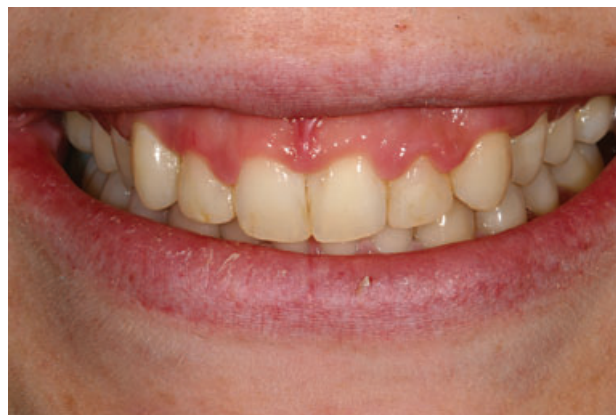

Figure 4. Adjunctive therapies, including periodontal plastic surgery, are recommended to optimize gingival contours for restorative treatment in the presence of severe gingival deformity.

more satisfactory esthetic outcome during interdisciplinary diagnosis and treatment.

The literature primarily consists of conjecture and has presented differing information on where the gingival zenith position (GZP) is located from the vertical bisected midline (VBM) axis of each individual maxillary anterior tooth and where it should be placed.^{1,4,5,9-11} Also absent is significant objective information regarding the gingival levels of the lateral incisors relative to the gingival line joining the tangents of the gingival zenith of the adjacent central and canine under healthy conditions. Recently, Charruel and colleagues investigated the gingival line angle (GLA) asymmetry between the right and left sides from the *frontal perspective only* using an analysis of study cast

photographs. They reported a directional asymmetry GLA difference of 4.1 ± 3 degrees for the right side. The GZP of the canine is apical to that of the incisors, and the gingival zenith level (GZL) of the lateral incisor is below 81.1% or on 15% of the gingival lines from the frontal view.¹² Lastly, the mean apical-coronal position of the lateral incisor GZL relative to the adjacent GZP was 0.68 ± 0.52 mm from the frontal perspective.

Limited research has been conducted to quantify these two clinical parameters: (1) the GZP from the VBM axis of each individual maxillary anterior tooth; and (2) the GZL (in an apical-coronal direction) of the lateral incisors relative to the gingival line joining the tangents of the gingival zenith of the adjacent

central and canine under healthy conditions.

The purpose of this investigation was thus to evaluate and establish these two clinical parameters. Through quantification strategies, diagnosis and treatment of gingival architecture discrepancies can be established for predictable treatment outcomes.

MATERIALS AND METHODS

A sample population of 20 patients (13 females, 7 males) with healthy gingival tissue (6 thick and 14 thin gingival phenotypes) was studied. The patients, who ranged in age from 20 to 47 years (mean 27.7 years), were in good systemic health. Criteria for inclusion in the sample population were nonrestored maxillary anterior teeth, those with no anterior crowding or

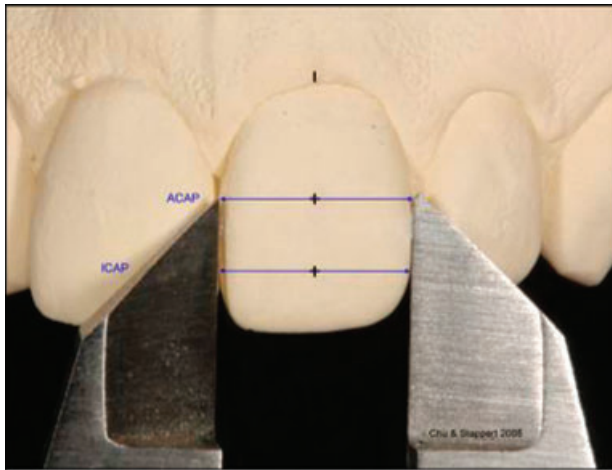


Figure 5. To define the vertical bisected midline of each clinical crown, the tooth width was measured at two reference points (digital calipers with LED display SAE/metric). The proximal incisal contact area position (ICAP) and the apical contact area position (ACAP) served as reference points.

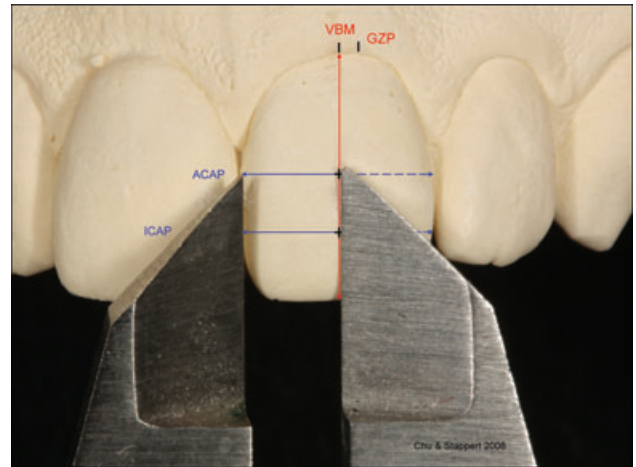


Figure 6. Each width was divided in half, and the center points were marked. Center points were extended to a line toward the gingival aspect of the clinical crown to define the vertical bisected midline (VBM). ACAP = apical contact area position; ICAP = incisal contact area position; GZP = gingival zenith position.

spacing, and teeth with no visible signs of excessive incisal attrition, gingival recession, gingival overgrowth, or altered passive eruption.

Alginate impressions of the study group were made using irreversible hydrocolloid impression material (Jeltrate, Dentsply Caulk, Milford, DE, USA) and were immediately poured with stone (Resin Rock, Whip Mix Corp., Louisville, KY, USA). A digital caliper with a light-emitting diode (LED) display was used to measure the 240 sites of the anterior maxillary teeth from canine to canine. Each cast was measured by an operator using 2.5 magnification optical loupes (Surgi-Tel, General Scientific Corp., Ann Arbor, MI, USA). Six-inch digital

calipers with LED display Society of Automotive Engineers (SAE)/metric (i.e., graduations: 0.01 mm, accuracy: ± 0.02 mm, repeatability: 0.01 mm) were used for measurement. Control measurements were completed by a second investigator. The caliper was calibrated prior to each measurement. To define the VBM of each clinical crown, the tooth width was measured at two reference points. The proximal incisal contact area position and the apical contact area position served as the reference points (Figure 5). Each width was divided in half, and the center points were marked. Center points were extended to a line toward the gingival aspect of the clinical crown to define the VBM (Figure 6). The highest point of the free gingival margin was

marked. The distance of the highest gingival margin position to the VBM was measured along the VBM of central incisors, lateral incisors, and canines to obtain the GZP in a medial-lateral direction (Figures 7 and 8). A gingival line (i.e., a line joining the tangents of the gingival zeniths of the central incisor and canine) joining maxillary centrals to the canines was drawn.^{11,13} The distance of the contour of the gingival margin for the lateral incisor was measured from the line to obtain the GZL in an apical-coronal direction of the lateral incisors relative to the adjacent central and canine gingival zenith points (Figure 9). This study was conducted according to the Declaration of Helsinki for clinical investigations. Statistical analyses were performed by

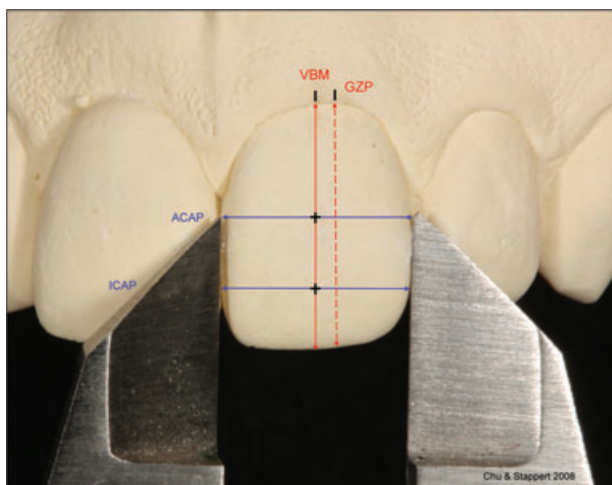


Figure 7. The highest point of the free gingival margin was marked. The distance of the highest gingival margin position to the vertical bisected midline (VBM) was measured along the VBM. Incisal and apical contact area reference positions, VBM, and gingival zenith position (GZP) are pictured. ACAP = apical contact area position; ICAP = incisal contact area position.

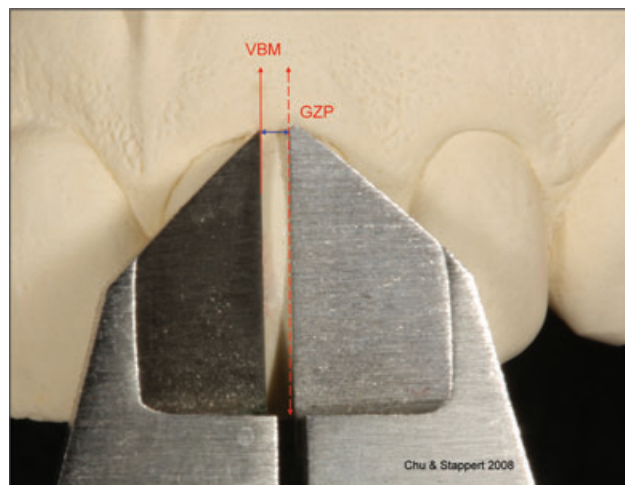


Figure 8. The highest point of the free gingival margin was measured from the vertical bisected midline (VBM) along the long axis of the tooth of the maxillary anterior dentition, including the central incisors, lateral incisors, and canine teeth, to obtain the gingival zenith position (GZP) in a medial-lateral direction.

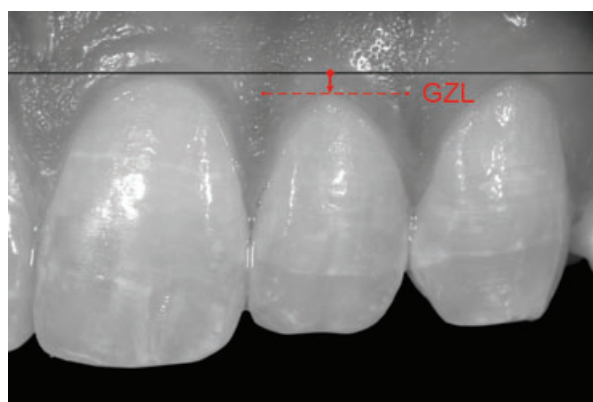


Figure 9. The distance of the contour of the gingival margin for the lateral incisor was measured from the line to obtain the gingival zenith level (GZL) in an apical-coronal direction of the lateral incisors relative to the adjacent central and canine gingival zenith points.

independent sample *t*-tests and paired samples correlations ($\alpha = 0.05$). To achieve a high degree of data accuracy for each anterior

tooth position, data were collected and calculated for each tooth position separately, and subsequently paired by tooth groups.

RESULTS

One hundred percent of central incisors displayed a distal GZP from the VBM. For lateral incisors, 65% of the population showed a distal displacement of GZP from the VBM, and 35% showed that the GZP was concurrent and centralized along the vertical axis of the tooth. Only 1 of 40 canine sites (2.5%) showed a distal displacement of GZP from the VBM (Figure 10). The mean distal distances of the GZP to the VBM of the clinical crown of central incisors, lateral incisors, and canines were 1.1, 0.4, and 0 mm, respectively. Table 1 shows the descriptive values of GZP distances to the VBM of clinical crowns of the

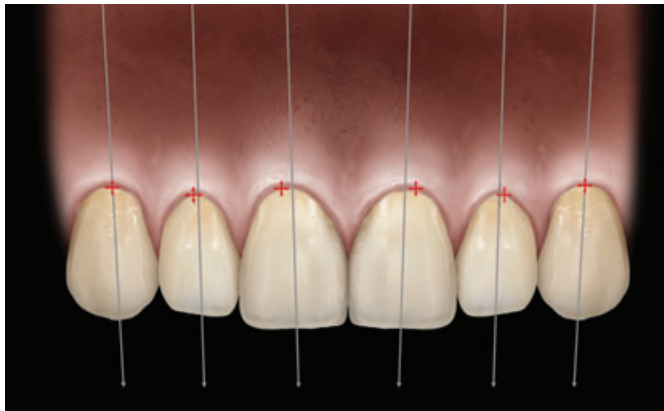


Figure 10. The mean distance of the gingival zenith position of the central incisor teeth was about 1 mm distal to the vertical bisected midline of the clinical crown. Clinically, the gingival zenith position of the lateral incisor and canine teeth are coincident with the vertical bisected midline along the axial inclination of the teeth.

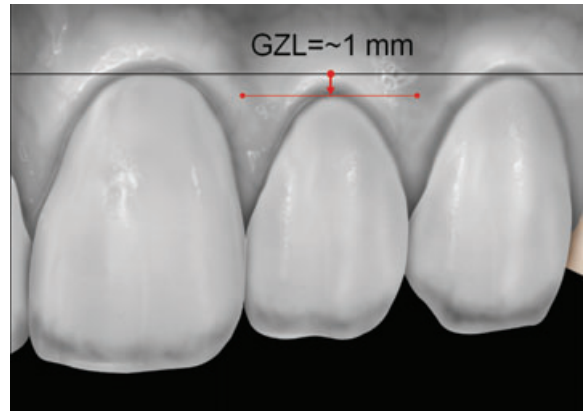

Figure 11. The gingival zenith level (GZL) for both right and left lateral incisors relative to the adjacent gingival zenith position of the central incisor and canine teeth were coronal by approximately 1 mm.

TABLE 1. DISTANCE OF THE GINGIVAL ZENITH POSITION (mm) DISTAL TO THE VERTICAL BIASECTED MIDLINE OF THE CLINICAL CROWN ALONG THE LONG AXIS (FIGURE 3), SORTED BY TOOTH POSITION AND TOOTH GROUPS.

Gingival Zenith Position	N	Group	Mean ± SD	Minimum	Maximum
#8	20	CI	1.1 ± 0.28	0.8	1.7
#9	20	CI	1.1 ± 0.28	0.6	1.5
#7	20	LI	0.4 ± 0.30	0	1
#10	20	LI	0.3 ± 0.31	0	0.9
#6	20	C	0 ± 0	0	0
#11	20	C	0 ± 0.12	0	0.5

CI = central incisors; LI = lateral incisors; C = canines.

TABLE 2. DISTANCE OF THE GINGIVAL ZENITH LEVEL (mm) OF THE LATERAL INCISORS (LI) IN AN APICAL-CORONAL DIRECTION RELATIVE TO THE GINGIVAL LINE, JOINING THE TANGENTS OF THE GINGIVAL ZENITH POSITION OF THE ADJACENT CENTRAL INCISOR AND CANINE TEETH (FIGURE 4).

Gingival Zenith Level	N	Group	Mean ± SD	Minimum	Maximum
#7	20	LI	0.94 ± 0.49	0	1.8
#10	20	LI	0.95 ± 0.46	0	1.6

CI = central incisors; LI = lateral incisors; C = canines.

maxillary anterior dentition. The GZP tends to be located at the VBM of canine crowns, whereas lateral incisors demonstrate a deviation of the gingival zenith by a mean of 0.4 mm and central incisors by 1 mm to the VBM of the clinical crown. These trends between the tooth groups were observed but were not statistically significant ($p \geq 0.115$; t -test/paired samples test).

The mean distance of the contour of the gingival margin in an apical-coronal direction of the lateral incisors (GZL) relative to the gingival line joining the tangent of the adjacent central and canine GZPs was approximately 1 mm. The range of values measured was 0 to 1.8 mm (Table 2, Figure 11).

DISCUSSION

Elements involved in designing an esthetic smile have been profoundly discussed in the dental literature.^{1,4,5,7,9-11} Details such as the GZP, the most apical point of the free gingival margin of the periodontium, and the GZL of the lateral incisor relative to the central incisors and canine teeth can significantly influence the esthetic appearance of a smile. However, these studies, though discussing various aspects related to the gingival contours of the maxillary anterior teeth, have presented conflicting information on where the GZP should be. The appropriate placement of the gingival zenith is critical, as it helps to determine the desired axial inclination of the tooth by maneuvering the line angle of the tooth vertical axis. Subsequently, knowing the GZP of each maxillary anterior tooth from the VBM as well as the GZL of the lateral incisors can help facilitate a reference point during esthetic periodontal plastic surgery procedures.

Magne and Belser suggested that the GZP was distal to the long axis of all the maxillary anterior teeth.¹ Rufenacht proposed that the GZP was distally displaced on the central incisors and canines only,^{4,5} whereas those of the lateral incisors were coincident with the VBM. Goodlin described the GZP for central incisors at the distal

third, laterals at the VBM, and canines ranging from the anterior third to the distal third of the VBM.¹⁴

Rufenacht suggested that for a Class 1 occlusion, the ideal GZL should be where the gingival contours of the central incisors and canines are at the same level and the lateral incisor positioned slightly more coronal. In Class 2, division 2 malocclusions, the GZL of the lateral incisors are more apical compared with that of the central incisors and canines, as the laterals tend to overlap the distal aspects of the central incisors.⁵ The subsequent tooth and root positions of the lateral incisors within the dental arch affect the gingival contours.

The findings reported herein are consistent with the GZP for the maxillary central incisors but are in disagreement with those for lateral incisors and canines. The GZP of the lateral incisors were almost concurrent with the VBM, and that of canines are coincident with the VBM within each tooth group. These quantified mean standards are representative for average tooth dimensions values of 8.3-mm width and 10.3-mm length.¹⁵ The GZL values presented herein differ by a mean of +0.3 mm (1–0.7 mm) from those reported by Charruel and colleagues since they measured photographs taken of diagnostic

casts from the frontal perspective ($SD = \pm 0.5$ mm) versus direct measurements of casts. Variations for photography variances were accounted for in that study. Only 15% of the lateral incisor GZLs were at the same level with the GZP of the central incisors and canine teeth. This finding was in concurrence with other studies.^{12,14,16,17}

CONCLUSIONS

The mean location of the GZP (Table 1) from the VBM of the clinical crown of central incisors, lateral incisors, and canines was about 1 mm, 0.4 mm distally, and 0 mm, respectively. The GZL (Table 2) in an apical-coronal direction of lateral incisors relative to the gingival tangential zenith line joining adjacent central incisor and canine was approximately 1 mm under healthy conditions. These reference points could be used in conjunction with other subjective and objective esthetic parameters during diagnosis, treatment planning, and in reconstructing a natural smile.

DISCLOSURE AND ACKNOWLEDGMENTS

The authors do not have any financial interest in the companies whose materials are included in this article.

We are grateful to Malvin Janal, PhD, Department of Psychiatry,

New Jersey Medical School, for carrying out the data analyses.

REFERENCES

1. Magne P, Belser U. Bonded porcelain restorations in the anterior dentition. A biomimetic approach. Carol Stream (IL): Quintessence; 2002, pp. 58–64.
2. Prichard J. Gingivoplasty, gingivectomy and osseous surgery. *J Periodontol* 1961;32:275–82.
3. Nordland WP, Tarnow DO. A classification system for loss of papillary height. *J Periodontol* 1998;69:1124–6.
4. Rufenacht CR. *Fundamentals of esthetics.* Berlin: Quintessence; 1990, pp. 67–134.
5. Rufenacht CR. *Principles of esthetic integration.* Chicago (IL): Quintessence; 2000, p. 154.
6. Hess D, Magne P, Belser U. Combined periodontal and prosthetic treatment. *Schweiz Monatsschr Zahnmed* 1994;104:1109–15.
7. Belser UC. Esthetics checklist for the fixed prosthesis. Part II: biscuit-bake try-in. In: Schärer P, Rinn LA, Kopp FR, editors. *Esthetic guidelines for restorative dentistry.* Chicago (IL): Quintessence; 1982. pp. 188–92.
8. Nathan Blitz SC. Criteria for success in creating beautiful smiles. *Oral Health and Dental Practice* 1997;87(12):38–42.
9. Chiche GJ, Pinault A. *Esthetics of anterior fixed prosthetics.* Chicago (IL): Quintessence; 1994.
10. Fradeani M. *Esthetic rehabilitation in fixed prosthodontics. Volume I—Esthetic analysis: a systematic approach to prosthetic treatment.* Chicago (IL): Quintessence; 2004.
11. Ahmad I. Geometric considerations in anterior dental aesthetics: restorative principles. *Pract Periodontics Aesthet Dent* 1998;10:813–22.
12. Charruel S, Perez C, Foti B, et al. Parameters for gingival contour assessment. *J Periodontol* 2008;79(5):795–801.
13. McGuire MK. Periodontal plastic surgery. *Dent Clin North Am* 1998;42:411–65.
14. Goodlin R. *Gingival aesthetics: a critical factor in smile design.* *Oral Health and Dental Practice* 2003;93(4):10–27.
15. Chu SJ, Tarnow DP, Tan JH, Stappert CF. *Papilla height to crown length proportions in the maxillary anterior dentition.* *Int J Periodont Rest Dent* 2009;in press.
16. Jones L. *Predictable “gum lifts” made easy.* *Oral Health and Dental Practice* 2003;93(4):65–75.
17. Parmar A. *Treating smile disease.* *R&AP* 2002;4(10):58–62.

Reprint requests: Stephen J. Chu, DMD, MSD, CDT, Clinical Associate Professor, Department of Periodontology and Implant Dentistry, New York University College of Dentistry, New York, NY, USA. Tel.: 212-752-7937; Fax: 212-754-6753; e-mail: schudmd@aol.com